

A Guide to Performing a Complete Standardised Echocardiographic Examination

In Great Apes

April 2015

Victoria Strong BVSc BSc (Hons) MRCVS

Mike Martin MVB DVC MRCVS, RCVS Specialist in Veterinary Cardiology

Sarah Chapman BVM&S MSc CertZooMed MRCVS

Malcolm Cobb MA Vet MB DVC PhD MBA FHEA MRCVS

Sharon Redrobe BVetMed BSc (Hons) DZooMed MRCVS

With the support of the Great Ape Heart Project (Zoo Atlanta, USA)

Ape Heart Project (Eaza Great Ape TAG Endorsed)

Twycross Zoo, Burton Road, Atherstone, Warwickshire, UK, CV9 3PX

Website: www.twycrosszoo.org/ape-heart-project.aspx Email: heartproject@twycrosszoo.org

GUIDELINES

A Guide to Performing a Complete Standardised Echocardiographic Examination in Great Apes

V. Strong^{1,2}, M. Martin³, S. Chapman², M. Cobb¹, S. Redrobe²

¹*School of Veterinary Medicine & Science, University of Nottingham, Sutton Bonington, LE12 5RD*

²*Twycross Zoo, Burton Road, Atherstone, Warwickshire, CV9 3PX*

³*Veterinary Cardiorespiratory Centre, 43 Waverley Road, Kenilworth, Warwickshire, CV8 1JL*

INTRODUCTION

This guide has been created as part of the EAZA Great Ape TAG endorsed Ape Heart Project. Based at Twycross Zoo (UK), the project is a Europe wide collaborative initiative striving to achieve a better understanding of great ape cardiovascular disease.

It is an ambition that all veterinarians, cardiologists and sonographers will find these guidelines useful when performing echocardiographic examinations on great apes.

The purpose of this protocol is to;

- Promote consistency and quality in performing cardiac assessment of great apes between different institutions and by multiple individuals
- Ensure that the same techniques are used when collecting data, thereby allowing comparison between information gathered from various sources
- Facilitate individual clinical assessment and disease screening

The echocardiographic examinations performed will aid in **clinical assessment** and therefore benefit the individual animals concerned. We ask that each examination is also submitted to the Great Ape Heart Project **database**. Information being gathered from this database will aid and improve the future diagnosis and management of great ape cardiovascular disease worldwide.

Ape Heart Project (EAZA Great Ape TAG Endorsed)

Twycross Zoo, Burton Road, Atherstone, Warwickshire, UK, CV9 3PX

Website: www.twycrosszoo.org/ape-heart-project.aspx Email: heartproject@twycrosszoo.org

SECTION 1: General Information

a. Identifying Information

All data collected should be clearly labelled with patient identifying information, including the following:

- Studbook number
- Species (and subspecies if known)
- Individual institution ID (name/number)
- Zoological collection (at the time of examination)
- Date of birth

Further information as requested in the cardiovascular examination form should also be provided. It is likely that the supervising zoo veterinarian will need to complete these fields:

- Examination date
- Sonographer/cardiologist name and contact details
- Weight
- Body measurements (see form for details)
- Body weight
- Current health problems and medications

b. Anaesthesia

These guidelines are written with the assumption that cardiac examination is being performed under anaesthesia. All anaesthetic drugs can affect the cardiovascular system. Detailed information regarding any drugs given, including doses and timings of administration should accompany every cardiac examination submitted to the database.

Some zoos are performing awake echocardiography and blood pressure assessment in great apes – if you are interested in receiving more information please contact us.

c. Examination submission

Following assessment, details of the examination (as requested in the cardiac examination form) should be submitted to the Great Ape Heart Project database. For details on how to do this, please see their website.³ Once a *complete* exam has been submitted a cardiac advisor will review the scan and provide comments and image quality feedback within 4-6 weeks*. This information will then be shared with the European team.

**If the animal is sick at the time of examination and you require a more rapid response, please communicate this directly with the GAHP at the time of exam submission*

d. Data storage and submission

Echocardiographic studies should be recorded as moving images (at least 3 cardiac cycles) and stored in a medium which allows for video playback. Stationary images, e.g. spectral Doppler studies and ECG strips can be provided as .jpeg images. The submitting institution should also retain original files for their reference.

Ape Heart Project (EAZA Great Ape TAG Endorsed)

Twycross Zoo, Burton Road, Atherstone, Warwickshire, UK, CV9 3PX

Website: www.twycrosszoo.org/ape-heart-project.aspx Email: heartproject@twycrosszoo.org

SECTION 2: A Protocol for Performing a Standard Transthoracic Echocardiogram

This protocol aims to provide a guideline for performing a transthoracic echocardiogram (TTE) in great apes. The concept is based upon the British Society of Echocardiography Minimum Dataset for humans².

This protocol provides a recommended sequence for performing a systematic study.

Please note that following this protocol provides a basic dataset only. This can be supplemented with additional images as indicated in the presence of abnormal pathology.

This protocol is not a final or definitive guide, but a consensus view that should evolve and adapt with the opinions of other experts in the field and as our knowledge develops and progresses.

a. Technical information

A standard **2-5MHZ transducer** is adequate in most cases for adults. For smaller individuals, a 5-10MHz transducer may be more appropriate.

Whilst not all sonographers have access to the technology for performing tissue Doppler, inclusion of this data in echocardiographic assessment is ideal and the collection of appropriate images and data are desirable.

b. Animal Preparation & Positioning

Echocardiographic examination is aided by placement of the animal in left lateral recumbency with the left arm above the shoulder (see Figure 1, right):

It is possible to perform the scan with the animal in dorsal recumbency if necessary.

The use of padding underneath the animal is recommended to prevent injury.

Images can be obtained by parting of the hair and application of gel; clipping is rarely required.

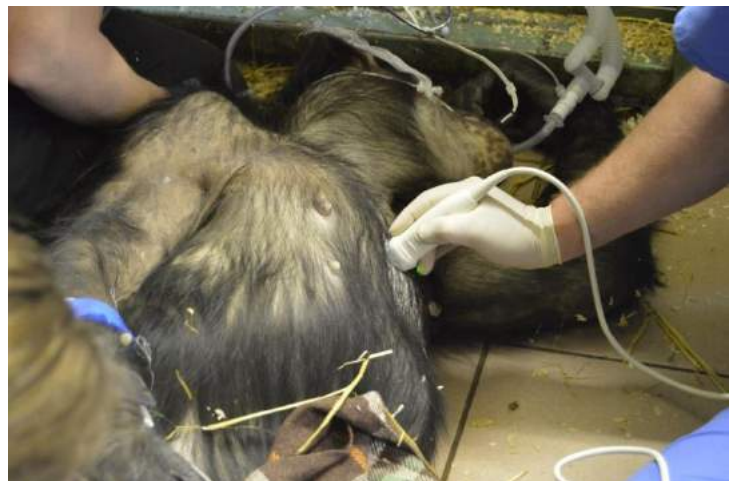

Figure 1: Chimpanzee positioned in left lateral recumbency for echocardiographic examination

Ape Heart Project (EAZA Great Ape TAG Endorsed)

Twycross Zoo, Burton Road, Atherstone, Warwickshire, UK, CV9 3PX

Website: www.twycrosszoo.org/ape-heart-project.aspx Email: heartproject@twycrosszoo.org

c. Acoustic Windows

Details regarding acoustic window location are provided in Table 1 below:

VIEW	ABBREVIATION	TRANSDUCER LOCATION	THUMB/NOTCH POSITION
Parasternal long axis	PLAX	3 rd -5 th ICS, close to sternum	Towards right shoulder, 10-11 o'clock position
Parasternal short axis	PSAX	Rotate transducer 90° from PLAX position	Towards left shoulder, 2-3 o'clock position
Apical four chamber	A4C	Left lateral chest, 5-6 th ICS, just below nipple, beam angled towards head	Towards left shoulder, 2-3 o'clock position
Apical five chamber	A5C	Tilt cranially from A4C view	As above
Apical two chamber	A2C	Rotation clockwise from A4C	As above

Table 1:
Table showing a guide to acoustic window positioning for obtaining standardised echocardiographic images
(ICS = intercostal space)

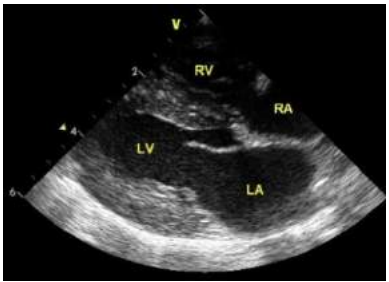


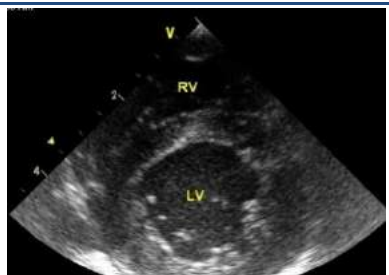
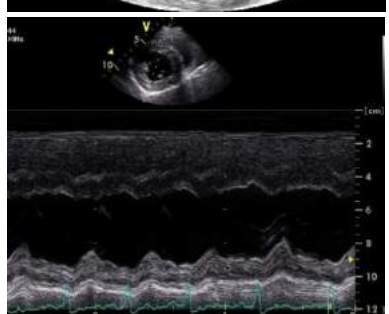
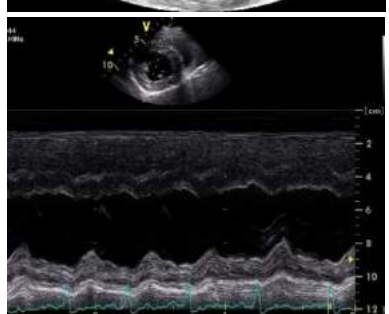
d. Image orientation

Please orientate the images as per the examples shown overleaf.

Ape Heart Project (EAZA Great Ape TAG Endorsed)

Twycross Zoo, Burton Road, Atherstone, Warwickshire, UK, CV9 3PX




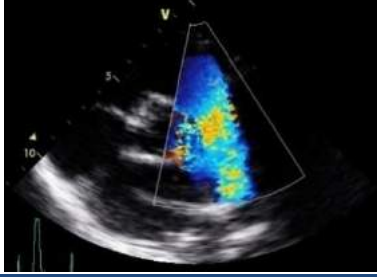

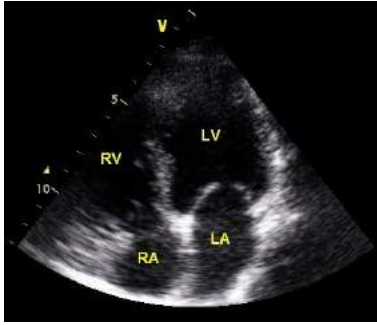
Website: www.twycrosszoo.org/ape-heart-project.aspx Email: heartproject@twycrosszoo.org

VIEW	MODALITY	VIEWS TO OPTIMISE	MEASUREMENTS	EXPLANATORY NOTE	SAMPLE IMAGE
PLAX	2D	LV, LA, MV		Ensure whole of LV and LA are visible Assess LV chamber size & check for any region wall motion abnormalities	
	2D + CFM	RA, RV (Adjust depth to optimise for right heart)	LA diameter (end ventricular systole, inner dimension)	Assess LA appearance and size. Assess MV appearance, structure and function Assess RV & RA chamber sizes	
	2D	Ao + LV		Assess appearance of AV/LVOT	
	2D +CFM			Screen for outflow turbulence and aortic regurgitation	
PSAX	2D	Screen LV from base to apex	LVIDd/s, IVSd, LVPWd in systole and diastole (2D or M-mode)	Ensure symmetry of papillary muscles and chordae tendineae Ensure endocardium of RV septum is visible Assess LV chamber size, function and wall thickness & check for any region wall motion abnormalities, scanning from apex to base	
	M mode		Measurements can alternatively be performed in PLAX view, if this images better	M-mode through LV at level of chordate	

Ape Heart Project (EAZA Great Ape TAG Endorsed)

Twycross Zoo, Burton Road, Atherstone, Warwickshire, UK, CV9 3PX


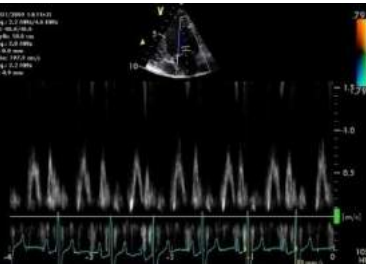
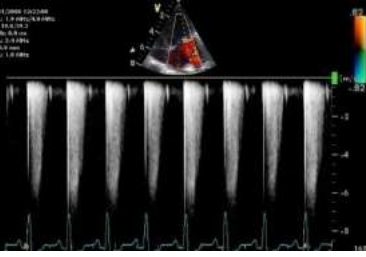


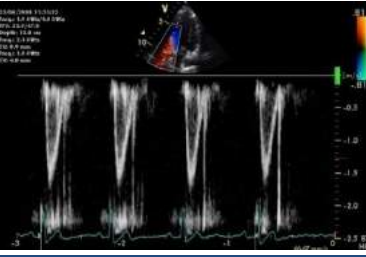
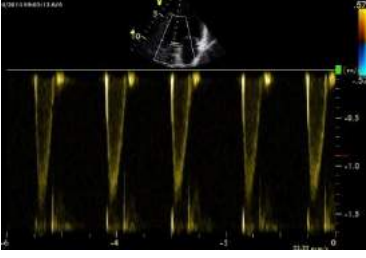
Website: www.twycrosszoo.org/ape-heart-project.aspx Email: heartproject@twycrosszoo.org

PSAX contd.	2D	MV		Assess MV structure and function	
	2D + CFM			Screen for MV regurgitation	
	2D	Aortic valve	Ao diameter	Ensure symmetry and good visualisation of 3 aortic valve cusps Assess structure of AV; measure AV diameter	
		LA	Max LA diameter & AV:LA ratio	Assess appearance of LA	
		PV		Ensure maximal length of RVOT to pulmonary artery visualised Assess structure and function of RVOT, PV & PA Assess appearance of RA & RV	
	2D + CFM	PV		Screen for PV turbulence and regurgitation	
	CW	PV regurgitation	PR V_{max}	If present; measure peak flow velocity of regurgitant jet	
PW	PV velocity	V_{max}	Measure peak flow velocity		
A4C	2D	All 4 chambers	MV EDV/ESV	Ensure endocardium is visible throughout LV (including apex) Assess LV chamber size, LV wall thickness & check for any region wall motion abnormalities	
	2D + CFM	MV, TV		Assess structure and function of MV and TV Screen for MV and TV regurgitation	

Ape Heart Project (EAZA Great Ape TAG Endorsed)

Twycross Zoo, Burton Road, Atherstone, Warwickshire, UK, CV9 3PX

Website: www.twycrosszoo.org/ape-heart-project.aspx Email: heartproject@twycrosszoo.org

A4C contd.	2D	LV (adjust depth to increase image size)	Measure LV volume (Simpson's rule) in diastole and systole and EF%)	Ensure endocardium is visible throughout (including apex). Measure LV volumes (systole and diastole)	
	PW	Mitral inflow Tricuspid inflow	Peak E & A wave velocities	Place cursor at level of MV leaflet tips and record inflow velocity Place cursor at level of TV leaflet tips and record inflow velocity	
	CW	MV or TV regurgitation	Peak velocity of any MR	If present; measure flow velocity of the regurgitant jet	
A2C	2D	LV	(Optional: LV volume in diastole & systole)	Ensure endocardium visible throughout (including apex). Assess LV chamber size and wall thickness & check for any regional wall motion abnormalities	
A5C	2D 2D +CFM	Ao& LV		Assess LV chamber size and wall thickness & check for any regional wall abnormalities Assess AV appearance & function Screen for AV turbulence & regurgitation	
	PW	AoV velocity	Peak Ao flow velocity	Place cursor just beyond AoV and record outflow velocity	
	CW	AoV regurgitation	Peak velocity AR	If present, measure flow velocity of regurgitant jet	

Ape Heart Project (EAZA Great Ape TAG Endorsed)

Twycross Zoo, Burton Road, Atherstone, Warwickshire, UK, CV9 3PX

Website: www.twycrosszoo.org/ape-heart-project.aspx Email: heartproject@twycrosszoo.org

Overleaf is
shortened
checklist
be a useful
memoir to
and refer
an

MEASUREMENTS

a
image
which may
aide
print off
to during

echocardiographic examination.

Checklist of information to be gathered during anaesthetic echocardiographic examination

Ape Heart Project (EAZA Great Ape TAG Endorsed)

Twycross Zoo, Burton Road, Atherstone, Warwickshire, UK, CV9 3PX

Website: www.twycrosszoo.org/ape-heart-project.aspx Email: heartproject@twycrosszoo.org

Weight (kg):		Body condition score (1-9):	
Crown-rump length (cm):			
BLOOD PRESSURE (During echocardiogram)			✓
Start	Systolic, diastolic and mean		
End	Systolic, diastolic and mean		
ECHOCARDIOGRAPHY			
View	Modality	Views to optimise	✓
PLAX	2D	LV LA MV	
	2D + CFM	MV	
	2D	Ao + LVOT	
	2D + CFM	AV	
	2D	RV RA	
	2D + CFM	TV	
PSAX	2D	LV (base to apex)	
	(M mode)	LV (level of chordae tendinae)	
	2D	MV	
	2D + CFM	MV	
	2D	AV LA RVOT + PV	
	2D + CFM	PV	
	CW*	PV regurgitation	
PW	PV velocities		
A4C	2D	All 4 chambers	
	2D	MV	
	2D + CFM	MV	
	PW	Mitral inflow	
	CW*	MV regurgitation	
	2D	TV	
	2D + CFM	TV	
	PW	Tricuspid inflow	
	CW*	TV regurgitation	
	2D	LV (zoomed in for volume measurements)	
A2C	2D	LV + LA	
A5C	2D	Ao + LV	
	2D + CFM	AV	
	CW*	AV regurgitation	
	PW	Aortic velocities	

Ape Heart Project (EAZA Great Ape TAG Endorsed)

Twycross Zoo, Burton Road, Atherstone, Warwickshire, UK, CV9 3PX

Website: www.twycrosszoo.org/ape-heart-project.aspx Email: heartproject@twycrosszoo.org

Acknowledgements:

With thanks to the Great Ape Heart Project (Zoo Atlanta, USA) for their assistance and support.

References:

¹ Cardiology Teaching Package: A Beginners Guide to Normal Heart Function, Sinus Rhythm & Common Cardiac Arrhythmias. University of Nottingham, School of Health Sciences;

http://www.nottingham.ac.uk/nursing/practice/resources/cardiology/function/chest_leads.php

² Wharton G. et al. 2012. A Minimum Dataset for a Standard Transthoracic Echocardiogram: From the British Society of Echocardiography Education Committee (Wharton G. (lead author), Steeds R. (chair), Allen J., Brewerton H., Jones R., Kanagala P., Lloyd G., Masani N., Matthew T., Oxborough D., Rana B., Sandoval J., Smith N., and Wheeler R.)

³ Great Ape Heart Project website: <http://greatapeheartproject.org/>

When performing a cardiac assessment on a great ape, please ensure that the **examination is submitted to the Great Ape Heart Project database.**

Further details and copies all of the forms and protocols can be downloaded from our project website (see below).

Very many thanks for supporting this project.

EAZA Great Ape TAG Endorsed Ape Heart Project
Website: www.twycrosszoo.org/ape-heart-project.aspx
Email: heartproject@twycrosszoo.org

Ape Heart Project (EAZA Great Ape TAG Endorsed)
Twycross Zoo, Burton Road, Atherstone, Warwickshire, UK, CV9 3PX
Website: www.twycrosszoo.org/ape-heart-project.aspx *Email:* heartproject@twycrosszoo.org